

## ORIGINAL RESEARCH

# Early angiographic occlusion of ruptured blister aneurysms of the internal carotid artery using the Pipeline Embolization Device as a primary treatment option

Yin C Hu,<sup>1,2,3</sup> Chandril Chugh,<sup>1</sup> Hasit Mehta,<sup>3</sup> Michael F Stiefel<sup>1,2,3</sup>

<sup>1</sup>NeuroVascular Institute, Westchester Medical Center, Valhalla, New York, USA  
<sup>2</sup>Department of Neurosurgery, New York Medical College, Valhalla, New York, USA  
<sup>3</sup>Department of Neuroradiology, Westchester Medical Center, New York Medical College, Valhalla, New York, USA

### Correspondence to

Dr Yin C Hu, Westchester Medical Center, New York Medical College, Taylor Pavilion, Suite-156, Valhalla, NY 10595, USA; [HuY@wcmc.com](mailto:HuY@wcmc.com)

Received 19 August 2013  
 Revised 9 November 2013  
 Accepted 15 November 2013  
 Published Online First 2 December 2013

### ABSTRACT

**Background** Data on the timing, durability and occlusion rate of treating ruptured blister cerebral aneurysms using the Pipeline Embolization Device (PED) are limited.

**Clinical presentation** Three patients who presented with subarachnoid hemorrhages from ruptured blister aneurysms of the internal carotid arteries were treated with the PED.

**Results** Aneurysmal occlusion with reconstruction of the parent vessels occurred angiographically using the PED as a primary treatment modality. All three patients were treated successfully without immediate or delayed complications and remained neurologically intact during the 6-month follow-up period.

**Conclusions** Complete occlusion of a ruptured blister aneurysm can occur immediately after PED placement. In ruptured blister aneurysms with contrast stagnation after PED treatment, early angiographic occlusion was confirmed as early as 6 weeks and continued with medium-term durability.

### INTRODUCTION

Ruptured blister aneurysms are technically challenging both for microsurgical and endovascular methods because of their fragility, small size and broad ill-defined neck.<sup>1–2</sup> Dissections often occur within the walls of the parent vessels forming a false aneurysmal wall.<sup>3</sup> Early recurrence frequently occurs despite satisfactory initial treatment, thus prompting diligent and constant surveillance of these lesions.<sup>4–7</sup>

The Pipeline Embolization Device (PED; eV3-Covidien, Irvine, California, USA) represents a significant new endovascular technology for the treatment of unruptured large aneurysms of the paraclinoid internal carotid artery (ICA). The role of the PED in patients with ruptured aneurysms—specifically blister aneurysms—has rarely been explored because of the pharmacological limitation for dual antiplatelet agents, mainly aspirin and clopidogrel. Patient outcomes and angiographic follow-up using the PED to treat these vascular lesions has been infrequently described in the literature.<sup>7–9</sup> The current case series demonstrates complete aneurysmal occlusion of a ruptured blister aneurysm immediately after PED treatment in one patient and as early as 6 weeks in two other patients with similar aneurysms.

### Case 1

A patient who presented with Hunt–Hess grade 2 Fisher grade 2 subarachnoid hemorrhage (SAH) complained of the worst headache of life (WHOL) and nausea. CT angiography (CTA) of the head and initial digital subtraction angiography (DSA) were negative for vascular abnormalities. Repeat DSA 1 week later demonstrated a 1.8 mm blister aneurysm at the ventral supraclinoid right ICA (figure 1A,B). A 4.25 mm×14 mm PED followed by a 4.25 mm×16 mm PED were successfully deployed across the aneurysm neck with contrast stagnation within the aneurysm.

### Case 2

An octogenarian presented as a Hunt–Hess grade 2 Fisher grade 1 SAH with 3 days of WHOL to an outside institution. Because of the clinical symptoms, a fluoroscopic lumbar puncture performed at the same institution detected positive xanthochromia in the cerebrospinal fluid indicative of recent SAH. Cerebral angiography revealed a 1.2 mm dorsal blister aneurysm of the left supraclinoid ICA (figure 2A). The aneurysm was treated with two PEDs (a 3.5 mm×14 mm PED followed by a 3.75 mm×18 mm PED). Contrast stagnation was noted within the aneurysm at the end of the procedure.

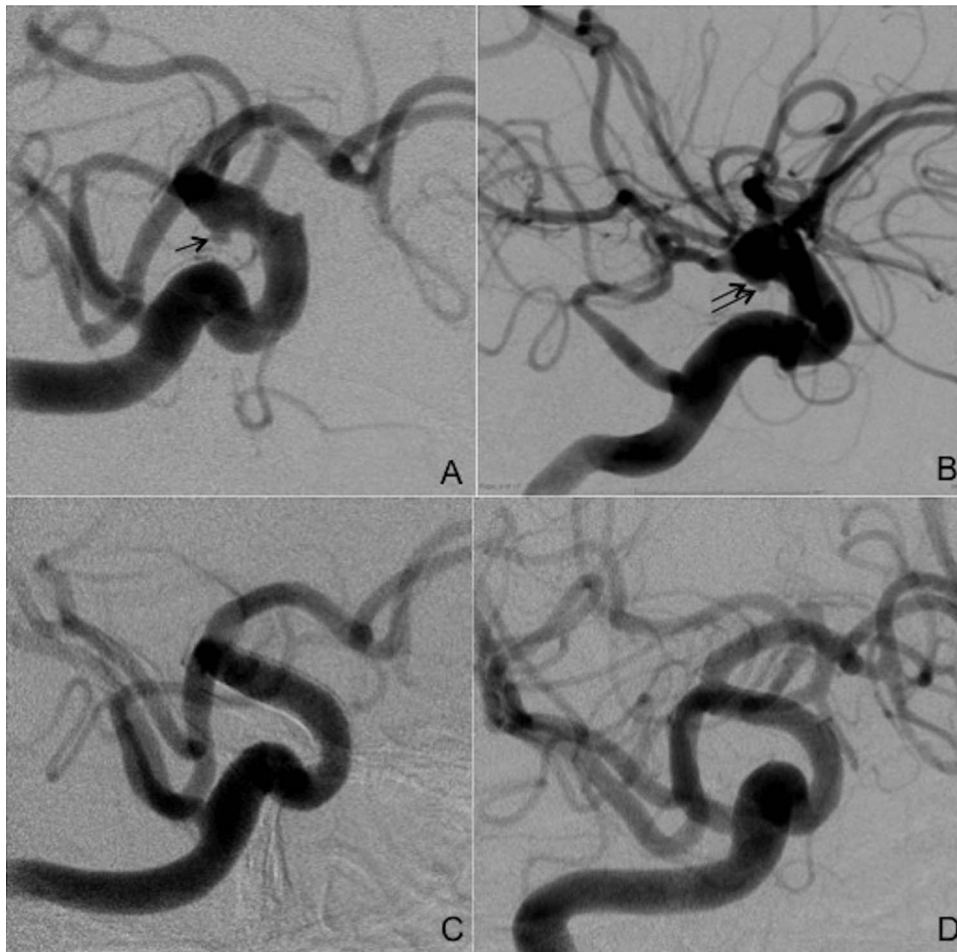
### Case 3

A patient presented with a Hunt–Hess grade 3 Fisher grade 3 SAH with WHOL. The patient noted that right-sided headaches had started 5 days previously but did not seek medical attention. CTA of the head showed a 1.5 mm blister aneurysm on the right dorsal supraclinoid ICA and a 4 mm left middle cerebral artery aneurysm (figure 3A). Initial DSA confirmed these findings (figure 3B). Since the patient had an external ventricular drain (EVD) placed for hydrocephalus and the headaches began approximately 5 days previously, the decision was made to wait and re-evaluate the blister aneurysm in a week with the intention to treat endovascularly after the EVD had been removed. Close surveillance with a repeat CTA of the head 3 days later showed stable aneurysms. The EVD was removed a week later. The second DSA demonstrated enlargement of the right supraclinoid ICA aneurysm, increasing to 3.5 mm (figure 3C). A 2.75 mm×10 mm PED followed by a 3 mm×12 mm PED were deployed



CrossMark

**To cite:** Hu YC, Chugh C, Mehta H, et al. *J NeuroIntervent Surg* 2014;**6**:740–743.



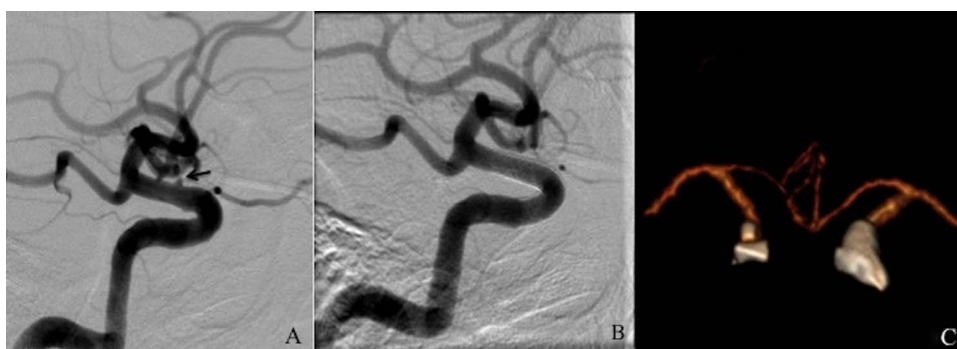**Figure 1** (A) Oblique and (B) lateral view digital subtraction angiograms (DSA) in patient 1 before deployment of the Pipeline Embolization Device (PED) showing a ventral supraclinoid paraclinoid internal carotid artery blister aneurysm (black arrow and double black arrows, respectively). (C) Angiographic aneurysmal occlusion occurred as early as 6 weeks after PED placement. (D) DSA at 9-month follow-up showing the aneurysm remaining occluded.

across the neck of the aneurysm with complete occlusion of the aneurysm.

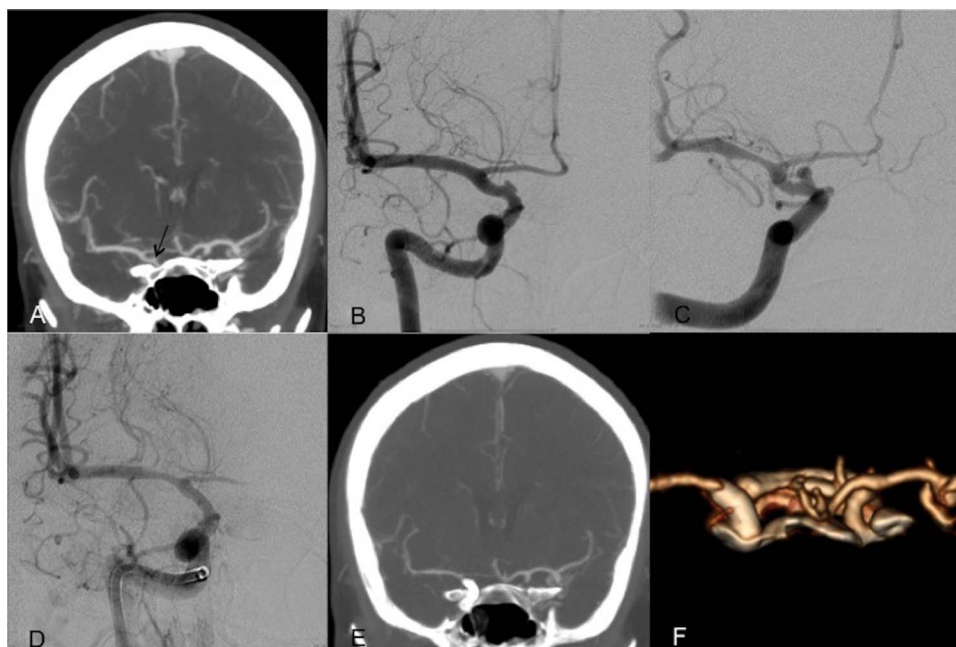
In each case an abciximab bolus (0.125 µg/kg) was given intravenously 10 min prior to PED placement. In patients 1 and 2, contrast stagnation was observed within the aneurysms after PED placement. In patient 3, complete aneurysmal occlusion was achieved after deploying the PED (figure 3D). A CT scan of the head was obtained immediately after the procedure for each

patient to confirm the absence of intracranial hemorrhage prior to loading of dual antiplatelet medications (650 mg aspirin and 600 mg clopidogrel). All patients were aspirin and clopidogrel responders. The patients were continued and discharged on daily aspirin (325 mg) and clopidogrel (75 mg).

The remaining hospital courses of the three patients were uneventful. Patients 1 and 2 were discharged home and early follow-up DSA was performed at 6 weeks (figure 1C) and



**Figure 2** (A) Digital subtraction angiogram in patient 2 before deployment of the Pipeline Embolization Device (PED) showing a dorsal supraclinoid paraclinoid internal carotid artery blister aneurysm (black arrow). The aneurysm remained occluded at 7 weeks (B) and 9 months (C) after PED placement.



**Figure 3** (A) Admission CT angiogram (CTA) of the head in patient 3 showing a ruptured blister aneurysm (black arrow). (B) Preoperative digital subtraction angiogram (DSA) showing a small broad-based medial projecting right dorsal supraclinoid paraclinoid internal carotid artery blister aneurysm. (C) DSA 1 week later showing enlargement of the aneurysm. (D) Late arterial phase angiogram following deployment of the Pipeline Embolization Device showing a completely occluded aneurysm without evidence of contrast stagnation in the aneurysm. (E) CTA of the head with three-dimensional reconstruction (F) 2 weeks later showing persistent occlusion of the aneurysm.

7 weeks (figure 2B), respectively. No residual aneurysms were detected. At 9-month imaging surveillance the treated aneurysms remained occluded for patient 1 (figure 1D) and patient 2 (figure 2C). At the recommendation of the vascular surgeon, a CTA of the head was performed for patient 2 instead of DSA because of the patient's peripheral vasculopathy and recent femoral bypass graft. For patient 3, a CTA of the head was performed 2 weeks later, which showed a persistent occluded aneurysm at the right ICA (figure 3E,F). Patient 3 was transferred to another country for rehabilitation. All patients remained neurologically intact (modified Rankin scale=0) at 6-month follow-up.

## DISCUSSION

Ruptured blister aneurysms of the intracranial circulation are challenging lesions for both microsurgical and endovascular interventions. The gold standard for the treatment of these lesions has not been established. The outcome from the different endovascular strategies varies in the literature.<sup>2 5 9 10</sup> Intraoperative rupture and delayed recurrence remain significant problems using stent-assisted coil embolization.<sup>2 5 11–13</sup> Other reports have described using multiple telescoping stents as a primary treatment modality<sup>14 15</sup> or delayed or staged endovascular procedures.<sup>4 16 17</sup> Flow diverters (ie, silk, PED) have provided a potential new treatment strategy for the treatment of ruptured blister aneurysms. Non-FDA approved flow diverters such as silk (Balt Extrusion, Montmorency, France) have been described in the literature for treating these lesions with medium-term success.<sup>18</sup> Because of the risks of using a dual antiplatelet regimen in patients with acute aneurysmal SAH, stents and their related devices have long been considered as a relative contraindication for the treatment of ruptured aneurysms. The increasing use of these devices (stents, flow diverters)

in acute ruptured aneurysms highlights an additional level of complexity in perioperative patient management.

Early recurrence treated by traditional endovascular methods emphasizes the need to address the following important questions regarding the use of the PED as a primary treatment modality for ruptured blister aneurysms: (1) What are the favorable and unfavorable patient characteristics that are associated with using PED? (2) How effective is the PED in treating these lesions? (3) What complications are associated with the necessary use of a dual antiplatelet regimen? In the current series, complete occlusion of a ruptured blister aneurysm using the PED as a first line of treatment occurred immediately in one patient. In the remaining two patients with aneurysmal contrast stagnation after PED deployment, aneurysmal occlusion occurred at postoperative weeks 6 and 7, respectively. The effect of the treatments lasted up to the last radiographic follow-up examinations at 9 months.

In very selective cases where the antiplatelet regimen may be less problematic during perioperative management, the PED may be considered as a reasonable primary option. Favorable patients are those with good Hunt–Hess grades who do not require an EVD and/or present several days after the initial aneurysmal rupture with a good neurological status. In patients with poor Hunt–Hess grades requiring prolonged EVD drainage and conversion to a ventriculoperitoneal shunt (VPS) or lumboperitoneal shunt (LPS), high risks of symptomatic clinical vasospasm and related neurological deficits and/or with diffuse cerebral edema, the PED may not be a suitable treatment strategy given the absolute need to reverse the effects of the antiplatelet agents for other possible surgical interventions (eg, hemicraniectomy, tracheostomy, percutaneous endoscopic gastrostomy, VPS or LPS). Adverse intracranial events following stent-assisted coiling while on dual antiplatelet agents have been described. A systematic review by Bodily *et al*<sup>19</sup> reported that

27 (8%) of 339 patients had clinically significant intracranial hemorrhagic complications including 9 (10%) of 90 patients associated with ventricular drain-related hemorrhage. Kung *et al*<sup>20</sup> also concluded that the rates of radiographic and symptomatic hemorrhage were significantly higher in the stent-assisted coil group than in the primary coil group (32% vs 14.7% and 8% vs 0.9%, respectively) when placement of an EVD or VPS is required. Conversely, a recent publication by Mahaney *et al*<sup>21</sup> suggests an increased but lower rate of symptomatic hemorrhage in patients on a dual antiplatelet regimen requiring a VPS after stent-assisted coil embolization of the aneurysm compared with other studies. To minimize these untoward events, several treatment strategies have been described. Soft passes without a stylet over the previous EVD track may reduce the risk of tract hemorrhages for insertion of a VPS.<sup>22</sup> A lumbar drain or LPS have been proposed as safer alternatives to an EVD or VPS, respectively, for patients on dual antiplatelet agents. However, devastating neurological declines have been observed and described by lumbar puncture in patients on aspirin and clopidogrel.<sup>23 24</sup>

The number of PEDs required to successfully treat ruptured blister aneurysms is also unknown. Multiple PEDs (minimum of two) may be required for the definitive treatment of ruptured blister aneurysms, although there is no definitive evidence to support this. Two characteristics of blister aneurysms may theoretically support this suggestion. First, these aneurysms often have a broad ill-defined neck and a false aneurysmal wall. The telescoping stent-in-stent technique increases the metal surface area over the diseased segment of the artery. Insufficient flow changes within the aneurysm may occur with traditional stents, leading to regrowth or rehemorrhage. The high surface area of a PED may reduce these events because of the increase in flow diversion away from the aneurysm. In addition, blister aneurysms often have dissections within the vessel wall forming false lumens; the overlapping configuration reinforces the weakened vessel walls to prevent further growth or recurrence associated with traditional endovascular methods. These PED features and technical considerations decrease the amount of intrasaccular flow and pressure and allow for progressive thrombosis of the aneurysm and reconstruction of the parent vasculature with lasting results.

## CONCLUSION

Blister aneurysms are rare lesions which are difficult to treat, with a high rate of recurrence or rehemorrhage despite adequate initial treatment. Although the series is small, our current experience suggests that, in carefully selected patients, the PED may be considered as a primary endovascular modality for treating ruptured blister aneurysms with excellent medium-term durability and clinical outcomes. Because these aneurysms are rare, pooled patient data from a number of centers are needed to further determine the overall safety, efficacy and durability of using the PED for the treatment of these lesions.

**Contributors** YCH, HM and MFS were involved in the conception and design or analysis and interpretation of data. YCH and CC drafted the article or revised it critically for important intellectual content. YCH and MFS approved the final version to be published.

**Competing interests** None.

**Provenance and peer review** Not commissioned; externally peer reviewed.

**Data sharing statement** De-identified datasets with full HIPAA compliance were used to tabulate the overall data for the patients in this retrospective case series.

## REFERENCES

- 1 Sim SY, Shin YS, Cho KG, *et al*. Blood blister-like aneurysms at nonbranching sites of the internal carotid artery. *J Neurosurg* 2006;105:400–5.
- 2 Meling TR, Sorteberg A, Bakke SJ, *et al*. Blood blister-like aneurysms of the internal carotid artery trunk causing subarachnoid hemorrhage: treatment and outcome. *J Neurosurg* 2008;108:662–71.
- 3 Abe M, Tabuchi K, Yokoyama H, *et al*. Blood blisterlike aneurysms of the internal carotid artery. *J Neurosurg* 1998;89:419–24.
- 4 Lee BH, Kim BM, Park MS, *et al*. Reconstructive endovascular treatment of ruptured blood blister-like aneurysms of the internal carotid artery. *J Neurosurg* 2009;110:431–6.
- 5 Park JH, Park IS, Han DH, *et al*. Endovascular treatment of blood blister-like aneurysms of the internal carotid artery. *J Neurosurg* 2007;106:812–19.
- 6 Lee CC, Hsieh TC, Wang YC, *et al*. Ruptured symptomatic internal carotid artery dorsal wall aneurysm with rapid configurational change. Clinical experience and management outcome: an original article. *Eur J Neurol* 2010;17:1277–84.
- 7 Consoli A, Nappini S, Renieri L, *et al*. Treatment of two blood blister-like aneurysms with flow diverter stenting. *J Neurointerv Surg* 2012;4:e4.
- 8 Martin AR, Cruz JP, Matouk CC, *et al*. The Pipeline flow-diverting stent for exclusion of ruptured intracranial aneurysms with difficult morphologies. *Neurosurgery* 2012;70(1 Suppl Operative):21–8.
- 9 Cruz JP, O’Kelly C, Kelly M, *et al*. Pipeline embolization device in aneurysmal subarachnoid hemorrhage. *AJNR Am J Neuroradiol* 2013;34:271–6.
- 10 Cinar C, Oran I, Bozkaya H, *et al*. Endovascular treatment of ruptured blister-like aneurysms with special reference to the flow-diverting strategy. *Neuroradiology* 2013;55:441–7.
- 11 Korja M, Rautio R, Valtonen S, *et al*. Primary treatment of ruptured blood blister-like aneurysms with stent-assisted coil embolization: report of two cases. *Acta Radiol* 2008;49:180–3.
- 12 Ihn YK, Kim SH, Sung JH, *et al*. The efficacy of endovascular treatment of ruptured blood blister-like aneurysms using stent-assisted coil embolization. *Interv Neuroradiol* 2012;18:432–41.
- 13 Meckel S, Singh TP, Urdren P, *et al*. Endovascular treatment using predominantly stent-assisted coil embolization and antiplatelet and anticoagulation management of ruptured blood blister-like aneurysms. *AJNR Am J Neuroradiol* 2011;32:764–71.
- 14 Chung J, Kim BM, Lim YC. Five overlapping enterprise stents in the internal carotid artery-to-middle cerebral artery to treat a ruptured blood blister-like aneurysm. *Neurol Sci* 2013;34:1485–7.
- 15 Kim YW, Park IS, Baik MW, *et al*. Endovascular treatment of blood blister-like aneurysms using multiple self-expanding stents. *J Korean Neurosurg Soc* 2011;49:116–19.
- 16 Ezaki Y, Takahata H, Kamada K, *et al*. Aneurysmal embolization of a blisterlike aneurysm of the internal carotid artery: a case report and review of the literature. *Surg Neurol* 2006;65:628–30.
- 17 Gaughen JR Jr, Hasan D, Dumont AS, *et al*. The efficacy of endovascular stenting in the treatment of supraclinoid internal carotid artery blister aneurysms using a stent-in-stent technique. *AJNR Am J Neuroradiol* 2010;31:1132–8.
- 18 Causin F, Pascarella R, Pavesi G, *et al*. Acute endovascular treatment (<48 h) of uncoilable ruptured aneurysms at non-branching sites using silk flow-diverting devices. *Interv Neuroradiol* 2011;17:357–64.
- 19 Bodily KD, Cloft HJ, Lanzino G, *et al*. Stent-assisted coiling in acutely ruptured intracranial aneurysms: a qualitative, systematic review of the literature. *AJNR Am J Neuroradiol* 2011;32:1232–6.
- 20 Kung DK, Policeni BA, Capuano AW, *et al*. Risk of ventriculostomy-related hemorrhage in patients with acutely ruptured aneurysms treated using stent-assisted coiling. *J Neurosurg* 2011;114:1021–7.
- 21 Mahaney KB, Chalouhi N, Viljoen S, *et al*. Risk of hemorrhagic complication associated with ventriculoperitoneal shunt placement in aneurysmal subarachnoid hemorrhage patients on dual antiplatelet therapy. *J Neurosurg* 2013;119:937–42.
- 22 Rammos S, Klopfenstein J, Augspurger L, *et al*. Conversion of external ventricular drains to ventriculoperitoneal shunts after aneurysmal subarachnoid hemorrhage: effects of site and protein/red blood cell counts on shunt infection and malfunction. *J Neurosurg* 2008;109:1001–4.
- 23 Mayumi T, Dohi S. Spinal subarachnoid hematoma after lumbar puncture in a patient receiving antiplatelet therapy. *Anesth Analg* 1983;62:777–9.
- 24 Paal P, Putz G, Gruber E, *et al*. Subarachnoid hemorrhage after lumbar puncture in a patient receiving aspirin and clopidogrel. *Anesth Analg* 2006;102:644–5.



# Early angiographic occlusion of ruptured blister aneurysms of the internal carotid artery using the Pipeline Embolization Device as a primary treatment option

Yin C Hu, Chandril Chugh, Hasit Mehta and Michael F Stiefel

*J NeuroIntervent Surg* 2014 6: 740-743 originally published online December 2, 2013

doi: 10.1136/neurintsurg-2013-010937

---

Updated information and services can be found at:  
<http://jnis.bmj.com/content/6/10/740>

---

## References

*These include:*

This article cites 24 articles, 7 of which you can access for free at:  
<http://jnis.bmj.com/content/6/10/740#BIBL>

## Email alerting service

Receive free email alerts when new articles cite this article. Sign up in the box at the top right corner of the online article.

---

## Topic Collections

Articles on similar topics can be found in the following collections

[Hemorrhagic stroke](#) (241)

---

## Notes

---

To request permissions go to:  
<http://group.bmj.com/group/rights-licensing/permissions>

To order reprints go to:  
<http://journals.bmj.com/cgi/reprintform>

To subscribe to BMJ go to:  
<http://group.bmj.com/subscribe/>